

Original Article

ROLE OF SDF-1 AND CELECOXIB IN INCREASING QUANTITY OF NEURAL STEM CELL IN THE LESION ZONE AND OUTCOME OF SPONTANEOUS INTRACEREBRAL HEMORRHAGE

ROBERT SINURAT^{a*}, ANI MELANI MASKOEN^b, DANY HILMANTO^b, KAHDAR WIRIADISASTRA^b

^aDepartment of Surgery, Medical Faculty, Christian University of Indonesia, ^bDoctoral Program, Medical Faculty, Padjadjaran University, Bandung, Indonesia
Email: robertsinurat@yahoo.com

Received: 13 Mar 2016 Revised and Accepted: 20 May 2016

ABSTRACT

Objective: We studied the effect of stromal derived factor-1 (SDF-1) and celecoxib for increasing the amount of neural stem cells in the lesion zone and clinical outcomes of spontaneous intracerebral hemorrhage.

Methods: Twenty-eight rats, strain Wistar, divided into four groups: control, treated with celecoxib, SDF-1, and the combination of celecoxib+SDF-1. The neural stem cells identified by immunohistochemistry procedures with Nestin as primary antibodies and the levels of proliferation were assessed by Ki-67 as primary antibodies. The clinical outcomes were examined by Bederson scale.

Results: This study revealed the combination treatment group had the highest histoscores of Nestin and highest of Ki-67 histoscores for SDF-1 group. The amount of neural stem cells in the lesion zone of treatments groups was higher than controls ($p < 0.005$), but similar between treated groups ($P > 0.05$). The proliferation levels were higher in SDF-1 group ($P < 0.05$), and the clinical outcomes back to normal were highest in combination therapeutic groups, even though not different when compared to another group ($p > 0.05$).

Conclusion: The results suggest celecoxib, SDF-1, and the combination of celecoxib+SDF-1 can increase neural stem cells in spontaneous intracerebral hemorrhage, and SDF-1 increased proliferation levels. The clinical outcomes were not significantly different between rats, regardless of the fact that almost all of rats in the combination group were back to normal.

Keywords: Neuroinflammation, Cyclooxygenase-2, Bederson Scale

© 2016 The Authors. Published by Innovare Academic Sciences Pvt Ltd. This is an open access article under the CC BY license (<http://creativecommons.org/licenses/by/4.0/>)

INTRODUCTION

Spontaneous intracerebral hemorrhage is one of disease when intracranial blood vessels ruptured, and the neurologic deficits will appear due to the neuron cells dead. Some risk factors of spontaneous intracerebral hemorrhage (SICH) are hypertension, diabetes mellitus and also hypercholesterolemia [1, 2]. The incidence of SICH in Asia almost 25%, and mortality rate between 34.6% until 42% all over the world [3-9]. One of dead cell mechanisms in SICH is neuroinflammation because of blood product degradation, leucocytes infiltration, and activated microglia. Cyclooxygenase-2 (cox2) is one of many toxic factors which expressed by activated microglia, and another were reactive oxygen species (ROS), matrix metalloproteinase (MMP), prostaglandin (PG), tumor necrotizing factor- α (TNF α), and interleukin 1 β (IL-1 β) [10-15].

When expression of cox2 increased, fas ligand (FasL) will be increased and cell death by apoptosis will start [16]. Neuron cells can also die from NMDA receptor-mediated glutamate toxicity, and inhibition of cox2 can protect the cells from those mechanisms [17]. Chu K *et al.* investigated of celecoxib as selective cox2 inhibitor in SICH models. They concluded that inflammation decreased, and clinical outcome of SICH models was better than controls [18]. Besides neuroinflammation process, there is neuro endogenesis in SICH which signed by migrated of neural stem cells from their niches in the hippocampus and subventricular zones. The migrations were influenced by stromal derived factor-1 (SDF-1). Unfortunately, most of the neural stem cells died and failed to change the death mature cells by SICH [19-22].

This study analyzed the effect of substitutes of SDF-1 as the migration factor for increasing the quantity of NSC migrates to the lesion zones and in combination with celecoxib as selective cox2 inhibitor decreased neuroinflammation to decrease cell death. While NSC increased in the lesion zone and neuroinflammation decreased, the quantity of survived NSC in the lesion zone will increase, and hopefully the outcome of SICH will be better.

MATERIALS AND METHODS

Twenty-eight male Wistar rats weight 200-300 grams were taken for the study. The rats were maintained in normal temperature room 28-31 °C, and free access to water and foods. The study was performed after approved by Health Research Ethical Committee of Padjadjaran University, West Java, Indonesia, with approval number 130/UN6.C2.1.2/KEPK/PN/2013-11st April 2013.

Intracerebral hemorrhage models

The rats were anesthetized with ketamine injected intramuscular using dose 1 mg/kg body weight. The skin of the head was washed by antiseptic and incised. The striatum was reached by a 26-G needle inserted 6.0 mm deep through a small burr hole made 3.5 mm right of and at the anteroposterior level of bregma. Then autologous blood (0.1 ml) was taken from the tail and infused to the striatum over 10 min, and the needle was removed slowly. The burr hole was sealed by bone wax, and the wound sutured [23, 24].

Treatment procedures

28 rats were divided randomly into 4 groups. The first group rats were not treated and assigned as a control. The second group rats were treated by injecting with celecoxib intraperitoneally with dose 20 mg/kg body weight, once a day for five days [12]. Meanwhile, the wounds of the third and fourth groups were reopened and inserted the 26-G needle to the lesion zone, then injected 0.1 ml SDF-1 with dose 500 ng/ml [25]. The needle was removed and the wound sutured. Beside SDF-1 treatment, the rats of the fourth group was injected with celecoxib intraperitoneally as same as the second group.

Temperatures and body weights

The temperatures and body weights of rats were measured before the procedures of intracerebral hemorrhage modeling, and the 14th day before the rats were euthanized with injected of 100 mg pentotal intraperitoneally.

Bederson scale and brain fixation

The clinical performances of rats were examined by Bederson scale at three hours after auto blood infusion of the striatum, and the 14th day before the rats euthanized. Bederson scale is divided into three categories: normal (no neurologic deficit), moderate (forelimb flexion), and severe when the forelimb was flexion with decreased resistance to lateral push, or circle to paretic side [26]. After euthanized, the brains were removed from the skulls and fixed by formalin and paraffin block. The histopathology process was done by immunohistochemistry using an antibody of Nestin and also Ki-67 under the light microscope at 400 x magnifications. The nestin marker was used to identify and counted of neural stem cells in the lesion zone, and Ki-67 for proliferation levels [19, 27, 28].

Immunohistochemistry

The immunohistochemistry was started with a block of paraffin, cut about 4-5 micron and coated, then incubated 38-40 °C one night. The tissues were deparaffinized by xylol and alcohol 90%, 80%, and 70%. Then the tissues were washed by water and hot sodium citrate buffer, entered to the decloaking chamber for 30 min. After cooled 30 min in temperature room and washed by Phospat Buffer Saline (PBS) for 5 min, tissues were peroxidase by H₂O₂. The tissues were rinsing with PBS and dropped by blocking serum before incubated for 10 min. The tissues were washed by PBS and gave primary antibody nestin. Incubated for 60 min, then rinsing by PBS. After rinsing with PBS, slides were incubated for 10 min at room temperature with biotin-conjugated secondary antibodies, attended by incubated with streptavidin-conjugated peroxidase working solution for 10 min. Subsequently, sections were stained for 10 min with 3, 3'-diaminobenzidine tetra hydrochloride (DAB), counter-

stained with haematoxylin, dehydrated, and mounted. Those procedures were further performed to another specimen using ki-67 as primary antibody [19, 28].

Semi-quantitative evaluation of Nestin and Ki-67 staining

The expression of nestin was examined as the intensity of staining by gave numerical with 0= negative, 1=light, 2= moderate, 3= intense. The different intensity percentages of positive cells were demonstrated as the ratio of positive cells. The final histoscore was 0-3, calculated from the sum of (0 x negative%, 1 x %weakly, 2 x % moderately, 3 x % intense). The cells proliferation were calculated by Ki-67 staining, which counted of the proportion of positive cell (chocolate nucleus) with whole cells, and results were: 0 (negative), 1 (<5% positive), 2 (5%-10% positive) and 3 (>10% positive).

Statistical analysis

Kolmogorov-smirnov test and analysis of variance (ANOVA) were used for the data of temperatures and body weights. Immunohistochemistry data and clinical outcomes were analyzed by ANOVA and Cross Tab (Chi-square test).

RESULTS

In this study, two of 28 eight spontaneous intracerebral rats were dead. One rat from controls was dead on the day after treatment because of bleeding in the cortical area, and the other one from the combination group was dead on the sixth day due to infection. The temperatures and body weights of rats showed in table 1. Based on homogeneity and Anova test, the temperatures and body weights of rats were similar, before and after treatment, p value>0.05, means the rates could be compared with each other as samples.

Table 1: Temperatures and body weights of rats before and after treatment

	Treatment groups				p
	Control	Celecoxib	SDF-1	Celecoxib +SDF-1	
1. Body weight day 1 (g):					
-Mean (SD)	218.0(5.5)	212.9(11.1)	208.7(8.6)	220.4(10.1)	0.098**
-Range	210-225	200-226	200-220	200-230	
2. Body weight day 14 (g):					
-Mean (SD)	228.5(14.5)*	226.0(14.7)*	213.4(12.0) *	230.8(14.1)*	0.129**
-Range	203-243	204-241	196-232	204-245	
3. Temperature day 1 (°C):					
-Mean (SD)	36.9 (0.4)	36.9 (0.4)	37.1 (0.3)	36.7 (0.2)	0.210**
-Range	36.4-37.5	36.4-37.6	36.6-37.4	36.4-36.9	
4. Temperature day 14 (°C):					
-Mean (SD)	37.1(0,3)*	36.9 (0.2) *	37.0 (0.3) *	36.9 (0.2)*	0.627**
-Range	36.6-37.5	36.5-37.2	36.6-37.4	36.6-37.2	

* No significant different between the first day and fourteenth days, p>0.05, **No significant different between controls and treated rats, based on analysis of variance (ANOVA), p>0.05

The immunohistochemistry pictures were seen in fig. 1, arrows showed neural stem cells with nestin expression (a) and ki-67 expression (b).

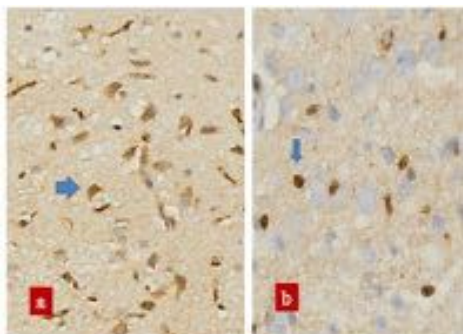


Fig. 1: Photomicrograph of immunohistochemistry, under light microscopes magnification 400x. a. Cell with immunorexpression of Nestin b. Cell with immunorexpression of Ki-67

The results of histoscores were seen in table 2. Histoscore of Ki-67 from all controls was negative, while only two from seven of celecoxib-treated rats were positive for proliferation<5%. All seven SDF-1 treated rats were positive, and most of them with proliferation<5%. Four of six combinations treated rats were positive with proliferation<5%, and two of them were negative.

The histoscore of nestin from all controls showed weakly positive, while most of the celecoxib-treated rats were moderately positive. On SDF-1 and combination treated rats, the nestin histoscore showed a balance between moderately positive and strongly positive.

The comparison of histoscore results between all groups was seen in table 3. The Ki-67 histoscore between controls and celecoxib groups were not different significantly, but higher on SDF-1 and combination groups. When comparing between SDF-1 and celecoxib groups, the Ki-67 histoscore was higher significantly different in SDF-1 group. Histoscore of nestin from all treatment groups was significantly higher than controls, but not different significantly between one treated to another treated groups.

Table 2: Immunohistochemistry results (Histoscore of Ki-67 and Nestin)

	Treatment groups			
	Control(n=6)	Celecoxib(n=7)	SDF-1(n=7)	Celecoxib+SDF-1 (n=6)
1. Histoscore Ki-67				
0	6	5	0	2
1	0	2	5	4
2	0	0	2	0
3	0	0	0	0
Mean(SD)	0(0)	0.28(0.5)	0.28(0.5)	0.67(0.5)
Median	0	0	1	1
Range	0	0-1	0-1	0-1
2. Histoscore Nestin				
0	0	0	0	0
1	6	1	1	1
2	0	4	3	2
3	0	2	3	3
Mean(SD)	1(0)	2.14(0.7)	2.28(0.7)	2.33(0.8)
Median	1	2	2	2.50
Range	1-1	1-3	1-3	1-3

Results of histoscore ki-67: 0 (negative), 1(<5% positive), 2(5%-10% positive);3(>10% positive); histoscore of nestin: 0(negative); 1(weakly); 2(moderately); 3(intense); n = amount of rats

Table 3: Comparisons of Ki-67 and Nestin histoscore

Group vs group	Histoscore Ki-67		Histoscore nestin	
	Z _{M-W}	p	Z _{M-W}	p
1. Control vs Celecoxib	1.268	0.171	2.847	0.004*
2. Control vs SDF-1	3.261	0.001**	2.832	0.005*
3. Control vs combination	2.345	0.019**	2.708	0.007*
4. Celecoxib vs SDF-1	2.734	0.006***	0.421	0.674
5. Celecoxib vs combination	1.320	0.187	0.544	0.587
6. SDF-1 vs combination	1.927	0.054	0.155	0.877

Combination: Celecoxib+SDF-1; Z_{M-W} = Mann-Whitney test, p<0.05, *Treated groups highly significant compared to control group, p<0.05, **SDF-1 and combination highly significant compared to control group, p<0.05, ***SDF-1 highly significant compared to celecoxib group, p<0.05

In table 4, the clinical outcome was reviewed and compared. After all, rats were infused by their auto blood to their striatum, all of them suffered a severe neurologic deficit. On 14th days, after treatments, half of control groups had a moderate neurologic deficit,

while most of the treatment groups were normal and especially in combination group only one rat had a moderate deficit. Even though clinical outcomes of treated rats group showed better than controls, but the chi-square test results did not show differently.

Table 4: Clinical outcome of SICH models by Bederson scale

Bederson scale	Treatment groups				p
	Control(n=7)	Celecoxib(n=7)	SDF-1(n=7)	Celecoxib+SDF-1 (n=7)	
1. Day 1 before treatment:					
-Normal	7	7	7	7	-
-Moderate	0	0	0	0	
-Severe	0	0	0	0	
2. Day 1 (3 h post-modeling):					
-Normal	0	0	0	0	-
-Moderate	0	0	0	0	
-Severe	7	7	7	7	
3. Day 14 (post treatment)					
-Normal	2*	4	4	5*	0.560**
-Moderate	3	1	2	1	
-Severe	1	2	1	0	

* One rat was dead, each group., ** Based on chi-square test, p<0.05, clinical outcome non-significant between treated groups and controls

DISCUSSION

The authors studied the role of celecoxib, SDF-1, and a combination of them for increasing the neural stem cells population in the lesion zone and their clinical impact for the outcome of spontaneous intracerebral hemorrhage in animal models. Twenty-eight rats successfully became SICH rats after auto blood transfusion into their striatum, showed severe neurologic deficit due to Bederson scale, but two rats were dropping out of the study because died before euthanasia due to infection and bleeding.

Histoscore of Ki-67 from controls and celecoxib groups were almost all negative. Suggest the proliferation level was low, and celecoxib did not impact the proliferation level. Some factors impacts proliferation levels in SICH already known were a basic fibroblast growth factor, epidermal growth factor, insulin like growth factor-1 and brain-derived neurotrophic factor (BDNF) started on 72 h after hemorrhage and peak on 7th days, then decreased until 28 d [19, 29, 30].

In the SDF-1 group revealed that histoscore Ki-67 were higher than the other groups, means SDF-1 impacts to increase the proliferation

level of cells in SICH. That issue is new, and supports Huang C *et al.*, and Arimitsu N *et al.* that stated interaction of SDF-1 and chemokine receptor type 4 (CXCR4) will activate mitogen-activated protein kinase (p38MAPK), ribosomal S6 kinase (RS6K), c-jun and Paxillin of stem cells, then activated proliferative and chemotaxis of stem cells [31, 32]. MAPK involved in the cell migration process by organized of actin, while RS6K was activated by extracellular signal-regulator kinases (ERK) and important for provoked phosphorylation process of cytoskeleton molecules, needed for migration and elongation of neurites. SDF-1 is playing the role of cell migration via CXCR4-SDF axis, and by different expression of SDF-1 in the niche and lesion zone. In this study, the quantity of SDF-1 in the lesion zone had to be added by substituting from outside, then the different level between lesion zone and niche becomes more and NSC increased in SDF-1 and combination group. This result supports Kokovay E *et al.* [25], Mori *et al.* [33], Kucia M *et al.* [34], and Imitola J *et al.* [35], studied SDF-1 involve for migrated and motility of cells.

Histoscoring of nestin revealed lowest in the control group, higher for celecoxib group, and highest of SDF-1 and combination groups. It means neural stem cells in the lesion zone were significantly increased by all treatment, especially for SDF-1 and combination groups. When there is no injury or inflammation, the neural stem cells were stated in the niche, subventricular zone and hippocampus [36]. NSC expressed intermediate filament protein (nestin), and the NSC can stay for a long time, do not involve in the cell cycle, and then died due to apoptosis [37-39]. When there is an injury of SICH, neural stem cells from niche migrated to lesion zone as the impact of thrombin, vascular endothelial growth factor (VEGF), and SDF-1 [32, 40]. Thrombin-mediated neurogenesis process via protease activated receptor-1 (PAR-1), and par-1 modulate angiotensin for angiogenesis [40]. Celecoxib decreased the inflammatory process by inhibited producers of Prostaglandin E2 (PGE2) and decreased fas ligand expression which important for activated apoptosis via caspase 8 and 3 [16, 41-43]. Cox2 inhibitor also inhibited N-methyl-D-aspartate (NMDA) receptor activation which increased calcium intra cell and mitochondrial failure, and cell death [17, 44-46].

Although NSC increased by the combination of SDF-1 and celecoxib, there were not significantly different between the combination group versus each treatment, SDF-1 or celecoxib groups. This result may be because of limited neural stem cells in the niche in one periodic time. It was also stated by Takahashi *et al.* [47], and Sommer L *et al.* [39], that neural stem cells divided in a limited time for six days and 10-12 cycles only. The highest good clinical of the rats were received in the combination group even though do not significant when measured by chi-square test. Maybe this result because of some controls could recover spontaneously, and also needed larger samples of rats for comparing the clinical outcomes.

CONCLUSION

Treatment of SICH with celecoxib or SDF-1 increased the quantity of neural stem cells in the lesion zone, but when treated with a combination of them did not increase more than a single treatment, due to limited of neural stem cells in the niche. The clinical outcomes of SICH were not significantly different between rats, even though most of the combination treated rats were almost normally. Interestingly, grading of proliferation was highest in the treatment of SDF-1 compared to another treatment, celecoxib or combination.

CONFLICT OF INTERESTS

Declared none

ACKNOWLEDGMENT

We thank dr. Betty H, SpPA, PhD (Dept of Pathology, Medical Faculty of Padjadjaran University) for helping the histopathology procedures and pictures.

REFERENCES

- Greenberg MS. Handbook of neurosurgery. 4th ed. Florida: Greenberg Graphics; 2008.
- Caplan LR. Caplan's stroke: a clinical approach. 4th ed. Philadelphia: Saunders Elsevier; 2009.

- Health Department of Indonesian Republic. Health profile of Indonesia 2008. Jakarta; 2009.
- Endres M, Dirnagl U, Moskowitz MA. The ischemic cascade and mediators of ischemic injury. In: Fisher M. editor. Handbook of clinical neurology. Vol. 92. Stroke part I: basic and epidemiological aspects. Edinburgh, Elsevier; 2009. p. 31-41.
- Qureshi AI, Tuhim S, Broderick JP, Batjer H, Hondo H, Hanley DF, *et al.* Spontaneous intracerebral hemorrhage. N Engl J Med 2001;344:1450-60.
- Yamada Y, Metoki N, Yoshida H, Satoh K, Kato K, Hibino T, *et al.* Genetic factors for ischemic and hemorrhagic stroke in Japanese individuals. Stroke 2008;39:2211-8.
- Sturm JW, Mackay MT, Thrift AG. Stroke among women, ethnic groups, young adults, and children. In: Fisher M. editor. Handbook of clinical neurology. Vol. 92. Stroke part I: basic and epidemiological aspects. Edinburgh, Elsevier; 2009. p. 337-53.
- Olsen TS. Stroke recurrence and prognoses after stroke. In: Fisher M. editor. Handbook of clinical neurology. Vol. 92. Stroke part I: basic and epidemiological aspects. Edinburgh, Elsevier; 2009. p. 407-21.
- Sinurat R. Outcomes of spontaneous intracerebral hemorrhage after surgery. Proceedings of 9th Asian Congress of Neurological Surgeons; Istanbul, Turkey; 2012.
- Caplan LR. Caplan's stroke: a clinical approach. 4ed. Philadelphia: Saunders Elsevier; 2009.
- Mengzhou X, Bigio D. Intracortical hemorrhage injury in rats: the relationship between blood fraction and cell death. Stroke 2000;31:1721-7.
- Wang J. Preclinical and clinical research on inflammation after intracerebral hemorrhage. Prog Neurobiol 2010;92:463-77.
- Wang J, Dore S. Heme oxygenase-1 exacerbates early brain injury after intracerebral haemorrhage. Brain 2007;130:1643-52.
- Shinohara Y. Hemorrhagic stroke syndromes: clinical manifestations of intracerebral and subarachnoid hemorrhage. In: Fisher M. editor. Handbook of clinical neurology. Vol. 93. Stroke part II: manifestations and pathogenesis. Edinburgh, Elsevier; 2009. p. 577-94.
- Loftspring MC, Hansen C, Clark JF. A novel brain injury mechanism after intracerebral hemorrhage: the interaction between heme products and the immune system. Med Hypotheses 2010;74:63-6.
- Callaghan GO, Kelly J, Shanahan F, Houston A. Prostaglandin E2 stimulates fas ligand expression via the EP1 receptor in colon cancer cells. Br J Cancer 2008;99:502-12.
- Hewett SJ, Uliasz TF, Vidwans AS, Hewett JA. Cyclooxygenase-2 contributes to N-methyl d-aspartate-mediated neuronal cell death in primary cortical cell culture. J Pharmacol Exp Ther 2000;293:417-25.
- Chu K, Jeong SW, Han SY, Lee ST, Kim M, Roh JK. Celecoxib induces functional recovery after intracerebral hemorrhage with reduction of brain edema and perihematomal cell death. J Cereb Blood Flow Metab 2004;24:926-33.
- Otero L, Zurita M, Bonilla C, Rico MA, Aguayo C, Rodriguez A, *et al.* Endogenous neurogenesis after intracerebral hemorrhage. Histol Histopathol 2012;27:1-13.
- Haas S, Weidner N, Winkler J. Adult stem cell therapy in stroke. Curr Opin Neurol 2005;18:59-64.
- Lindvall O, Kokaia Z. Recovery and rehabilitation in stroke. Stroke 2004;35:2691-4.
- Shen J, Xie L, Mao XO, Zhou Y, Zhan R, Greenberg DA, *et al.* Neurogenesis after primary intracerebral hemorrhage in adult human brain. J Cereb Blood Flow Metab 2008;28:1460-8.
- MacLellan CL, Silasi G, Auriat AM, Colbourne F. Rodent models of intracerebral hemorrhage. Stroke 2010;41(10 Suppl):S95-8.
- MacLellan CL, Silasi G, Poon CC, Edmunson CL, Buist R, Peeling J. Intracerebral hemorrhage models in rat: comparing collagenase to blood infusion. J Cereb Blood Flow Metab 2008;28:516-25.
- Kokovay E, Goderie S, Wang Y, Lotz S, Lin G, Sun Y, *et al.* Adult SVZ lineage cells home and to leave the vascular niche via differential responses to SDF1/CXCR4 signaling. Cell Stem Cells 2010;7:163-73.
- Bederson JB, Pitts LH, Tsuji M, Nishimura MC, Davis RL, Bartkowski H. Rat middle cerebral occlusion: evaluation of the

- model and development of a neurologic examination. *Stroke* 1986;17:472-6.
27. Du K, Peng Y, Zhang L, Liang A, Huang D. Expression of the stem cell marker nestin in pre/hypertrophic chondrocytes in osteochondroma. *J Int Med Res* 2011;39:348-57.
 28. Kee N, Sivalingam S, Boonstra R, Wojtowicz JM. The utility of Ki-67 and BrdU as proliferative markers of adult neurogenesis. *J Neurosci Methods* 2002;115:97-105.
 29. Bulwinkel J, Luhr BB, Ludeman A, Wohlenberg C, Gerdes J, Scholzen T. Ki-67 protein is associated with ribosomal RNA transcription in quiescent and proliferating cells. *J Cell Physiol* 2006;3:624-35.
 30. Zhang RL, Zhang ZG, Zhang L, Chopp M. Proliferation and differentiation of progenitor cells in the cortex and the subventricular zone in the adult rat after focal cerebral ischemia. *Neuroscience* 2001;105:33-41.
 31. Huang C, Rajfur Z, Borchers C, Schaller MD, Jacobson K. JNK phosphorylates paxillin and regulates cell migration. *Nature* 2003;424:219-22.
 32. Arimitsu N, Shimizu J, Fujiwara N, Takai K, Takada E, Kono T, *et al.* Role of SDF1/CXCR4 interaction in experimental hemiplegic models with neural cell transplantation. *Int J Mol Sci* 2012;13:2636-49.
 33. Mori T, Doi R, Koizumi M, Toyoda E, Ito D, Kami K, *et al.* CXCR4 antagonist inhibits stromal cell-derived factor 1-induced migration and invasion of human pancreatic cancer. *Mol Cancer Ther* 2004;3:29-36.
 34. Kucia M, Reza R, Miekus K, Wanzeczek, Wojakowski W, Wiecek AJ, *et al.* Trafficking of normal stem cells involve similar mechanisms: pivotal role of the SDF-1—CXCR4 axis. *Stem Cells* 2005;23:879-94.
 35. Imitola J, Raddassi K, Park KI, Mueller FJ, Nieto M, Teng YD, *et al.* Directed migration of neural stem cells to sites of CNS injury by the stromal-cell-derived factor 1/cxcr4 chemokine receptor pathway. *Proc Natl Acad Sci* 2004;101:18117-22.
 36. Buyla A, Verdugo G, Tramontin AD. Unified hypothesis on the lineage of neural stem cells. *Neuroscience* 2001;2:287-93.
 37. Kornblum HI. Stem cells and stroke recovery: an introduction. *Stroke* 2007;38:810-6.
 38. Maslov YA, Barone TA, Plunkett RJ, Pruitt SC. Neural stem cell detection, characterization, and age-related changes in the subventricular zone of mice. *J Neurosci* 2004;24:1726-33.
 39. Sommer L, Rao M. Neural stem cells and regulation of cell number. *Prog Neurobiol* 2002;66:1-18.
 40. Yang S, Song S, Hua Y, Nakamura T, Keep RF, Xi G. Effects of thrombin on neurogenesis after intracerebral hemorrhage. *Stroke* 2008;39:2079-84.
 41. Nogawa S, Zhang F, Ross M, Iadecola C. Cyclo-oxygenase-2 gene expression in neurons contributes to ischemic brain damage. *J Neurosci* 1997;17:2746-55.
 42. Sinn DI, Lee ST, Chu K, Jung KH, Song EC, Kim JM, *et al.* Combined neuroprotective effects of celecoxib and memantine in experimental intracerebral hemorrhage. *Neurosci Lett* 2007;411:238-42.
 43. Gong C, Ennis SR, Hoff JT, Keep RF. Inducible cyclooxygenase-2 expression after experimental intracerebral hemorrhage. *Brain Res* 2001;901:38-46.
 44. Kawano T, Anrather J, Zhou P, Park L, Wang G, Frye KA. Prostaglandin E2 EP1 receptors: downstream effectors of COX-2 neurotoxicity. *Nat Med* 2006;12:225-9.
 45. Zhou P, Qian L, Chou T, Iadecola C. Neuroprotection by PGE2 receptor EP1 inhibition involves the PTEN/AKT pathway. *Neurobiol Dis* 2008;29:543-51.
 46. Andreasson K. Prostaglandin signaling in cerebral ischemia. *Br J Pharmacol* 2010;160:844-6.
 47. Takahashi T, Nowakowski RS, Caviness Jr VS. Mode of cell proliferation in the developing mouse neocortex. *Proc Natl Acad Sci* 1994;91:375-9.

How to cite this article

Robert Sinurat, Ani Melani Maskoen, Dany Hilmanto, Kahdar Wiriadisastra. Role of sdf-1 and celecoxib in increasing quantity of neural stem cell in the lesion zone and outcome of spontaneous intracerebral hemorrhage. *Int J Pharm Pharm Sci* 2016;8(7):399-403.