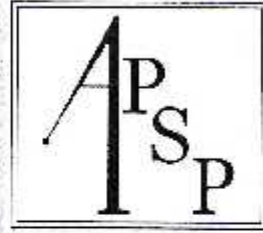


Dr. Ina



CURRENT ISSUES IN PERIODONTICS

Editors
PM Bartold
Y Kemal

**Proceedings of the
11th Asian Pacific Society of Periodontology Meeting
Bali, Indonesia
2015**

Aug. Inc

Program & Abstracts

11th Asian Pacific Society of Periodontology Meeting

October 8-9th, 2015
Discovery Kartika Plaza Hotel
South Bali, INDONESIA



Current Issues of Periodontics

11thapsp2015-Bali.iperi.org





VESTIBULOPLASTY WITH PRF:(CASE REPORT)

Drg Yulia Santi (Student of PPDGS Periodontia FKG UNPAD)
Drg Ina Hendiani SpPerio (K) (Tutor dept Periodontia FKG UNPAD)

ABSTRACT

Introduction: Vestibuloplasty should be performed in case of shallow vestibule. There are different techniques of vestibuloplasty. A number material are used as graft in vestibuloplasty like gingival graft or PRF. **Objectives:** Vestibuloplasty was a technique, originally used to increase the zone of attached gingiva at the same time that the vestibule was being deepened, eliminate the muscle insertion, reposition the mucosa and recession. The intended use PRF on vestibuloplasty procedur to help the healing process and substitute gingival graft. **Case:** Patient, female 39 years old with bad oral hygiene, recession class 3 (miller) in lower anterior and shallow vestibule performed maintenance with vestibuloplasty used as a single technique or as the preliminary step in preparing a rigid recipient bed for PRF. Examination reveals the mucogingival junction close or at gingival margin. **Case Management:** In these case report we have done initial therapy (scalling and rootplaning) and vestibuloplasty procedure single technique with PRF. **Conclusion:** After After initial therapy and vestibuloplasty procedur performed, oral hygiene to be good, no gingival inflammation detected, PRF can help healing process and maintains postoperative vestibular depth

Key words : Vestibuloplasty, deepened vestibule, single technique, PRF